

Extracorporeal shock wave therapy for calcifying tendinitis of the shoulder

Chin-Jung Hsu, MD, Der-Yean Wang, MD, Kuo-Fung Tseng, MD, Yi-Chin Fong, MD, Horng-Chaung Hsu, MD, and Yick-Fung Jim, MD, Taichung, Taiwan

We prospectively studied extracorporeal shock wave therapy (ESWT) for calcific tendinitis of the shoulder in 46 consecutive patients. All patients were randomly divided into 2 groups: treatment and control. The 33 patients in the treatment group received 2 courses of ESWT at the energy density of 0.55 mJ/mm² (1000 impulses). The control group underwent sham treatment with a dummy electrode (13 patients). Evaluation included the Constant score, pain scale, and radiographs. The ESWT results were good to excellent in 87.9% of shoulders (29/33) and fair in 12.1% (4/33), and the control results were fair in 69.2% (9/13) and poor in 30.1% (4/13). Among ESWT patients, calcium deposits were completely eliminated in 7 cases (21.2%), partially eliminated in 11 (36.3%), and unchanged in 15 (45.4%). In contrast, elimination was partial in 2 control patients (15.3%) and unchanged in 11 (84.7%). There was no significant difference between Gärtner type I and type II groups in the Constant score ($P > .05$). ESWT shows promise for pain relief and functional restoration of calcific tendinitis with negligible complications. (*J Shoulder Elbow Surg* 2008;17:55-59.)

Over the past 30 years, extracorporeal shock wave lithotripsy has been considered by urologists to be the gold standard in treating renal calculi, and the revolutionary method has almost completely replaced invasive surgery worldwide. More recently, extracorporeal shock wave therapy (ESWT) has been used to treat conditions such as nonunion of fractures, lateral epicondylitis, plantar fasciitis, and calcific tendinitis of the shoulder. It has shown promise in the promotion of fracture healing and repair of tendinopathies.^{11,13,16,17}

From the Departments of Orthopaedics and Radiology, China Medical University Hospital.

Reprint requests: Horng-Chaung Hsu, MD, Department of Orthopaedics, China Medical University Hospital, 2, Yuh-Der Rd, Taichung 404, Taiwan (E-mail: hchsuh@mail.cmc.edu.tw).

Copyright © 2008 by Journal of Shoulder and Elbow Surgery Board of Trustees.

1058-2746/2008/\$34.00

doi:10.1016/j.jse.2007.03.023

Calcific tendinitis as a source of shoulder pain was initially described more than 100 years ago as *maladie de Duplay*.¹³ Current treatment includes physiotherapy, nonsteroidal anti-inflammatory drugs, steroid injection, and surgical intervention to remove calcium deposits and decompress the subacromial space. Treatment of patients with calcific tendinitis is typically conservative. Reported success rates range between 30% and 85%.^{6,7,10,12,13,19} If pain becomes chronic or intermittent after several months of conservative treatment, surgery is often recommended. The effects of these different treatments vary significantly, and they do not show consistent and reliable long-term results.

ESWT represents a new, noninvasive treatment for calcific tendinitis of the shoulder. We conducted a randomized, prospective study using ESWT as treatment in a consecutive series of patients seen at our institution.

MATERIALS AND METHODS

Forty-six consecutive patients with chronic calcific tendinitis of the shoulder were recruited prospectively from July 2002 to February 2004. All patients were randomly divided into 2 groups: treatment and control. The randomization applied in this study was based on consecutive patients diagnosed at our hospital. The allocation ratio was set as 2:1 for intervention and placebo groups. Thus, systematic random sampling by 3 and its multiples was used in this series of cases to assign placebo subjects, without considering whether she or he refused to participate or met the exclusion criteria. Patients in the treatment group received ESWT, whereas control patients underwent sham shock wave treatment. Inclusion criteria included shoulder pain attributable to calcific tendinitis that had failed to respond to at least 3 months of nonoperative treatment. Nonoperative treatment included nonsteroidal anti-inflammatory drugs, corticosteroid injections, physical therapy, an exercise program, and immobilization of the shoulder in a sling. Exclusion criteria included a history of previous shoulder surgery, pregnancy, rotator cuff tear, malignancy, local infection, presence of cardiac pacemaker, use of anticoagulants, clotting problems, generalized polyarthritis, arthritis of the shoulder, or age under 18 years.

Before each application of ESWT or sham treatment, 10 mL of 2% lidocaine was injected into the affected area from a lateral approach with a 24-gauge needle. Ultrasound gel

was used as a contact medium between the transducer head and the skin. ESWT was administered in 2 sessions that were 2 weeks apart. Each session consisted of 1000 acoustic shock wave pulses delivered to the affected area by use of the OrthoWave machine (MTS, Konstanz, Germany) set at level 5. At this setting, the OrthoWave machine generates 2 pulses per second with an energy density of 0.55 mJ/mm. The most commonly encountered adverse reactions after ESWT included pain, local irritation, skin changes such as redness or bruising, swelling, and hematoma formation; all adverse reactions were recorded. After treatment, each patient was instructed to ice the shoulder for 48 hours. Orthopaedic examinations were done before ESWT sessions, and there were additional assessments at 6 weeks, 12 weeks, 6 months, and 1 year after the final ESWT session.²

An anteroposterior (AP) radiograph of the affected shoulder with the arm in neutral rotation was obtained before ESWT and taken at each of the 4 follow-up examinations. The calcific deposits were categorized according to morphology, and size (the longest length of the calcium deposit) was recorded. The morphologic features of the deposit had to be homogeneous in appearance and have well-defined borders (corresponding to type I in the classification of Gärtner³), nonhomogeneous in structure with a sharp outline, or homogeneous in structure with no defined border (corresponding to type II in the Gärtner classification). Resorption was graded as none, partial, or complete per AP view by a radiologist who was blinded to treatment status and antecedent studies.

Evaluation of function was done independently of the treating orthopaedic surgeon at baseline (before ESWT) and after 6 weeks, 12 weeks, 6 months, and 1 year. The 100-point Constant scoring system was used, with 15 points for pain, 20 points for activities of daily living, 40 points for shoulder motion, and 25 points for power of the affected arm.² Intensity of pain was measured with a visual analog scale ranging from 0 to 10, with 10 points being the worst score and 0 points being the best score. Scores before and after treatment were compared statistically by use of the Wilcoxon signed rank test. Scores between the treatment and control groups were compared by use of the Mann-Whitney test. The level of significance, α , was set to 5% for each test; therefore, $P < .05$ was considered significant.

RESULTS

The ESWT group consisted of 18 women and 15 men (mean age, 54.4 years; range, 30-70 years). The right shoulder was affected in 30 cases and the left in 3. The mean duration of the condition at the time of treatment was 12.3 months (range, 6-72 months).

The control group consisted of 9 women and 4 men (mean age, 57.8 years; range, 44-82 years). The right shoulder was affected in 12 cases and the left in 1. The mean duration of the condition at the time of treatment was 11.1 months (range, 6-30 months).

In the ESWT group, the pain scale score decreased from 7.2 before ESWT to 3.7, 2.1, 1.6, and 1.3 at 6 weeks, 12 weeks, 6 months, and 1 year, respectively.

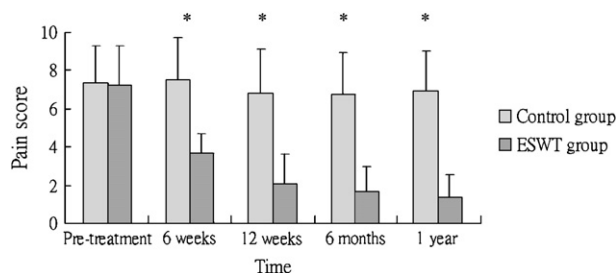


Figure 1 Pain scores for control patients (light gray bars) and ESWT patients (dark gray bars). After treatment, a statistically significant difference was observed between the ESWT and control groups ($P < .05$ [asterisks]).

In the control group, pain scale scores persisted at the same high pretreatment level. Comparative results before and after treatment for the ESWT and control groups are shown in Figure 1. Before treatment, no statistically significant difference was observed between groups. After treatment, a statistically significant difference was observed between the ESWT and control groups ($P < .001$). Improvement after treatment was statistically significant for the ESWT group ($P < .001$) but not for the control group ($P > .05$).

In the ESWT group, the Constant score increased from 57.3 before ESWT to 74.3, 82.8, 85, and 88 at 6 weeks, 12 weeks, 6 months, and 1 year after treatment, respectively. In the control group, the Constant score was essentially unchanged with time, from a score of 56.2 before ESWT to 57.3, 54.3, and 56.8 at 6 weeks, 12 weeks, and 6 months after treatment, respectively. Comparative results of Constant scores before and after treatment between patient groups are shown in Figure 2. Before treatment, no statistically significant difference was observed between the 2 groups. After treatment, a statistically significant difference was observed between the ESWT and control groups ($P < .001$). Improvement after treatment was statistically significant for the ESWT group ($P < .001$) but not for the control group ($P > .05$). Overall results in the ESWT group were good to excellent in 87.9% of shoulders (29/33) and fair in 12.1% (4/33). In contrast, results for the control group were fair in 69.2% of shoulders (9/13) and poor in 30.1% (4/13).

There were local erythematous changes over shock application sites in 3 of 33 ESWT patients (9.1%). No neurovascular complications were noted. For local discomfort, ice packing on the treatment area along with administration of acetaminophen resolved all complaints. Patient satisfaction in the ESWT group increased from 62.0% at 6 weeks to 83% 1 year after ESWT.

On AP radiography of the shoulder, the mean width of deposits in the ESWT group was 11.9 ± 5.4 mm

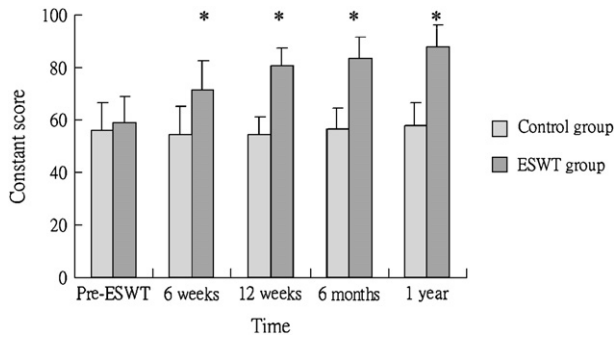


Figure 2 Constant scores for control patients (light gray bars) and ESWT patients (dark gray bars). After treatment, a statistically significant difference was observed between the ESWT and control groups ($P < .05$ [asterisks]).

(range, 3.4-23.5 mm). The mean width of deposits in the control group was 10.5 ± 6.4 mm (range, 2.5-20.4 mm). After ESWT treatment, the mean width of deposits decreased to 5.5 ± 6.3 mm (range, 0-18.7 mm). In contrast, the mean width of deposits in the control group after sham treatment was 9.8 ± 5.9 mm (range, 2.3-21.0 mm). These data represent a significant reduction in mean size of calcium deposits after therapy for the ESWT group ($P < .001$) but not for the control group ($P = .415$).

The ESWT group consisted of 22 Gärtner type I deposits and 11 Gärtner type II deposits. The mean width of deposits among Gärtner type I lesions was 9.9 ± 4.7 mm (range, 3.4-16.9 mm). The mean width of deposits among Gärtner type II lesions was 15.5 ± 5.1 mm (range, 8.24-23.5 mm). There was no significance in width of deposit in terms of overall therapeutic results and type of calcium deposit. We correlated the Constant score and morphologic pattern of the deposit, but there was no statistically significant difference in response between the 2 groups (Gärtner type I and type II lesions) to ESWT ($P = .37$) (Figure 3).

In the ESWT group, calcium deposits were completely eliminated in 7 cases (21.2%), partially eliminated in 11 (36.3%), and unchanged in 15 (45.4%). We noted fragmentation of calcium deposits in 6 patients as early as 6 weeks after ESWT. None of the patients in whom complete elimination of calcium deposits was obtained showed any recurrence of calcium deposits at 1 year after shock wave therapy. Among control patients, calcium deposits were completely eliminated in no patient, partially eliminated in 2 (15.3%), and unchanged in 11 (84.7%). We could not detect any fragmentation of calcium deposits. Of the 7 ESWT patients who had complete elimination of calcium deposits, 6 were complaint-free and had normal Constant scores whereas the remaining patient, who had mild pain, had a Constant score of 85 points. Of the 11 patients who had partial elimination of calcium deposits, 7 were complaint-free

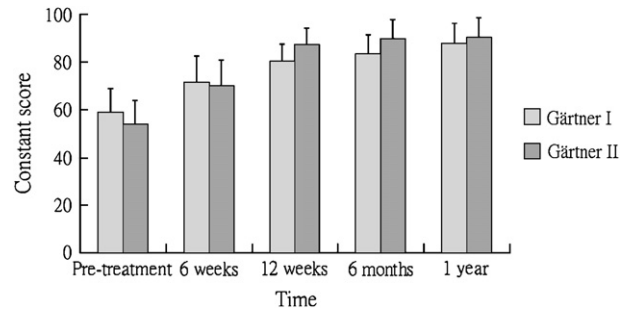


Figure 3 Constant scores for Gärtner type I deposits (light gray bars) and Gärtner type II deposits (dark gray bars). There was no statistically significant difference in response between the 2 groups (Gärtner type I and type II lesions) to ESWT.

and had normal Constant scores, 3 patients had significant improvement, and the remaining patient had moderate pain.

DISCUSSION

The exact cause of calcific tendinitis of the shoulder is unknown, although a degenerative process with an inflammatory reaction may play an important role.^{1,4,5} Nonoperative treatment is directed toward reducing pain and improving function. Thus far, multiple therapies have been advocated, ranging from rest or stretching and strengthening exercises to nonsteroidal anti-inflammatory medications or steroid injection to surgical intervention to remove calcium deposits and decompress the subacromial space. The effects of these different treatments vary significantly; moreover, the standard treatments do not show consistent and reliable long-term results. From our results, we conclude that ESWT is an effective method for treating calcific tendinitis of the shoulder.

The mechanism by which shock wave therapy acts is not yet known. However, there have been several studies showing apparent improvement in patients with calcific tendinitis of the shoulder treated with shock wave therapy. Rompe et al¹³ conducted a prospective study of 40 patients referred for persistent calcific tendinitis of the shoulder. At 24 weeks' follow-up after ESWT, statistically significant improvement was found in both subjective and objective criteria, with the Constant score reaching a normal value in 60% of the patients. Nearly three quarters (72.5%) of those patients had no or occasional discomfort, and only 6 of 40 patients (15%) reported no improvement after 24 weeks. Loew and Jurgowski⁷ prospectively studied 20 patients who underwent ESWT for calcific tendinitis of the shoulder. At the 12-week post-treatment evaluation, 15 (75%) had a marked reduction in symptoms. Subjective and functional states, as measured by Constant score, improved by a mean of 30%. In our study, the Constant score improved from

57.3 points before ESWT to 88 points at the 1-year follow-up after ESWT.

The mechanism of calcium deposit dissolution is not clearly known either. Calcium deposits are eliminated after shock wave therapy through a molecular mechanism of absorption associated with improved circulation at the tendon-bone junction. Ludwig et al⁸ reported pain relief and improved Harris scores 1 year after shock wave therapy in 22 patients with femoral head necrosis; they believed success was a result of improved circulation after shock wave therapy.

Wang et al^{18,20} showed that shock wave therapy enhanced neovascularization at the tendon-bone junction in dog and rabbit models. Their studies also showed that shock waves induce neovascularization at the tendon junction with early release of angiogenesis-mediating growth and proliferating factors, including endothelial nitric oxide synthase, vascular endothelial growth factor, and proliferating cell anti-nuclear antigen, all of which lead to improved blood supply and tissue regeneration. They concluded that shock wave therapy relieved shoulder symptoms by alternating focal circulation and regeneration.^{15,22}

In a study by Loew and Jurgowski,⁷ radiographs showed partial disintegration of the calcifying nucleus in 5 patients, with complete elimination of calcification in 7. Rompe et al¹³ noted partial or complete elimination at the 24-month follow-up in 62.5% of patients, whereas Wang et al²¹ reported partial or complete elimination at the 24-month follow-up in 57.6% of patients. Spindler et al¹⁴ noted that fragmentation of calcium occurred as early as 24 hours after shock therapy. Wang et al¹⁹ noted fragmentation in 3 cases. In our study, calcium deposits were completely eliminated in 7 cases (21.2%), partially eliminated in 11 (36.3%), and unchanged in the remaining 15 (45.4%). We noted fragmentation of calcium deposits in 6 patients at the 6-week post-ESWT evaluation. The actual interval for dissolution of calcium deposits to become apparent is not known, but dissolution of calcium deposits has been observed between 6 weeks and 6 months after ESWT.

The relationship of calcium deposits to shoulder pain is unclear. The goals of treatment are to alleviate pain and to restore shoulder function. Could we predict the clinical outcome by evaluating the size of calcium deposits and morphology of the calcifications on radiography? According to our results, there was no statistically significant difference in response to ESWT between Gärtner type I and Gärtner type II lesions in terms of Constant score ($P > .05$). Maier et al⁹ treated 62 patients (65 shoulders) with chronic calcific tendinitis with ESWT. They used radiographs to evaluate the size and morphology of calcifications. After ESWT (mean follow-up, 18.2 months), clinical evaluations of all 65 shoulders revealed an increase in Constant score from 44% to 78% ($P < .0001$).

The size and morphology of calcium deposits before ESWT is given were not associated with clinical outcome.⁹

One question for clinicians using ESWT is the choice of second-line treatment for the patient who does not respond to ESWT. According to reports by Wang et al,^{19,21} preliminary results of shock wave therapy for calcific tendinitis of the shoulder showed good or excellent outcomes in 62% of patients at 3- to 6-month follow-up evaluations. However, their most recent study showed that 90.9% of patients had obtained complete or nearly complete resolution of symptoms 2 years after shock wave therapy.²¹ They noted that the effects of shock wave therapy for calcific tendinitis of the shoulder appear to be cumulative and time-dependent. In our study, we noted that the Constant score and pain scale score did not significantly improve after 6 months after ESWT. Thus, we suggest that patients who do not see improvement after ESWT in that time frame should consider other forms of treatment.

In conclusion, treatment of calcific tendinitis of the shoulder with shock waves has produced a high rate of success in pain relief and functional restoration with negligible associated complications. ESWT is a new therapeutic modality that appears to be both safe and effective for these patients.

REFERENCES

1. Archer RS, Bayley JI, Acher CW, Ali SY. Cell and matrix changes associated with pathological calcification of the human rotator cuff tendons. *J Anat* 1993;182(Pt 2):1-11.
2. Constant CR, Murley AH. A clinical method of functional assessment of the shoulder. *Clin Orthop Relat Res* 1987;160-4.
3. Gärtner J. Tendinosis calcarea—results of treatment with needling [in German]. *Z Orthop Ihre Grenzgeb* 1993;131:461-9.
4. Gärtner J, Simons B. Analysis of calcific deposits in calcifying tendinitis. *Clin Orthop Relat Res* 1990;111-20.
5. Hayes CW, Conway WF. Calcium hydroxyapatite deposition disease. *Radiographics* 1990;1:1031-48.
6. Loew M, Daecke W, Kusnierczak D, Rahmzadeh M, Ewerbeck V. Shock-wave therapy is effective for chronic calcifying tendinitis of the shoulder. *J Bone Joint Surg Br* 1999;81:863-7.
7. Loew M, Jurgowski W. Treatment of calcifying tendinitis of rotator cuff by extracorporeal shock waves: A preliminary report. *J Shoulder Elbow Surg* 1995;4:101-6.
8. Ludwig J, Lauber S, Lauber HJ, Dreisilker U, Raedel R, Hotzinger H. High-energy shock wave treatment of femoral head necrosis in adults. *Clin Orthop Relat Res* 2001;119-26.
9. Maier M, Stabler A, Lienemann A, Kohler S, Feitenhansl A, Durr HR, et al. Shockwave application in calcifying tendinitis of the shoulder—prediction of outcome by imaging. *Arch Orthop Trauma Surg* 2000;120:493-8.
10. Ogden JA, Alvarez RG, Levitt R, Marlow M. Shock wave therapy (orthotripsy) in musculoskeletal disorders. *Clin Orthop Relat Res* 2001;22-40.
11. Rompe JD, Rosendahl T, Schollner C, Theis C. High-energy extracorporeal shock wave treatment of nonunions. *Clin Orthop Relat Res* 2001;102-11.
12. Rompe JD, Rumler F, Hoph C, Nafe B, Heine J. Extracorporeal shock wave therapy for calcifying tendinitis of the shoulder. *Clin Orthop Relat Res* 1995;196-201.

13. Rompe JD, Zoellner J, Nafe B. Shock wave therapy versus conventional surgery in the treatment of calcifying tendinitis of the shoulder. *Clin Orthop Relat Res* 2001;72:82.
14. Spindler A, Berman A, Lucero E, Braier M. Extracorporeal shock wave treatment for chronic calcific tendinitis of the shoulder. *J Rheumatol* 1998;25:1161-3.
15. Wang CJ. An overview of shock wave therapy in musculoskeletal disorders. *Chang Gung Med J* 2003;26:220-32.
16. Wang CJ, Chen HS, Chen CE, Yang KD. Treatment of nonunions of long bone fractures with shock waves. *Clin Orthop Relat Res* 2001:95-101.
17. Wang CJ, Chen HS. Shock wave therapy for patients with lateral epicondylitis of the elbow: a one- to two-year follow-up study. *Am J Sports Med* 2002;30:422-5.
18. Wang CJ, Huang HY, Pai CH. Shock wave-enhanced neovascularization at the tendon-bone junction: an experiment in dogs. *J Foot Ankle Surg* 2002;41:16-22.
19. Wang CJ, Ko JY, Chen HS. Treatment of calcifying tendinitis of the shoulder with shock wave therapy. *Clin Orthop Relat Res* 2001:83-9.
20. Wang CJ, Wang FS, Yang KD, Weng LH, Hsu CC, Huang CS, et al. Shock wave therapy induces neovascularization at the tendon-bone junction. A study in rabbits. *J Orthop Res* 2003;21:984-9.
21. Wang CJ, Yang KD, Wang FS, Chen HH, Wang JW. Shock wave therapy for calcific tendinitis of the shoulder: a prospective clinical study with two-year follow-up. *Am J Sports Med* 2003;31:425-30.
22. Wang FS, Wang CJ, Huang HJ, Chung H, Chen RF, Yang KD. Physical shock wave mediates membrane hyperpolarization and Ras activation for osteogenesis in human bone marrow stromal cells. *Biochem Biophys Res Commun* 2001;287:648-55.